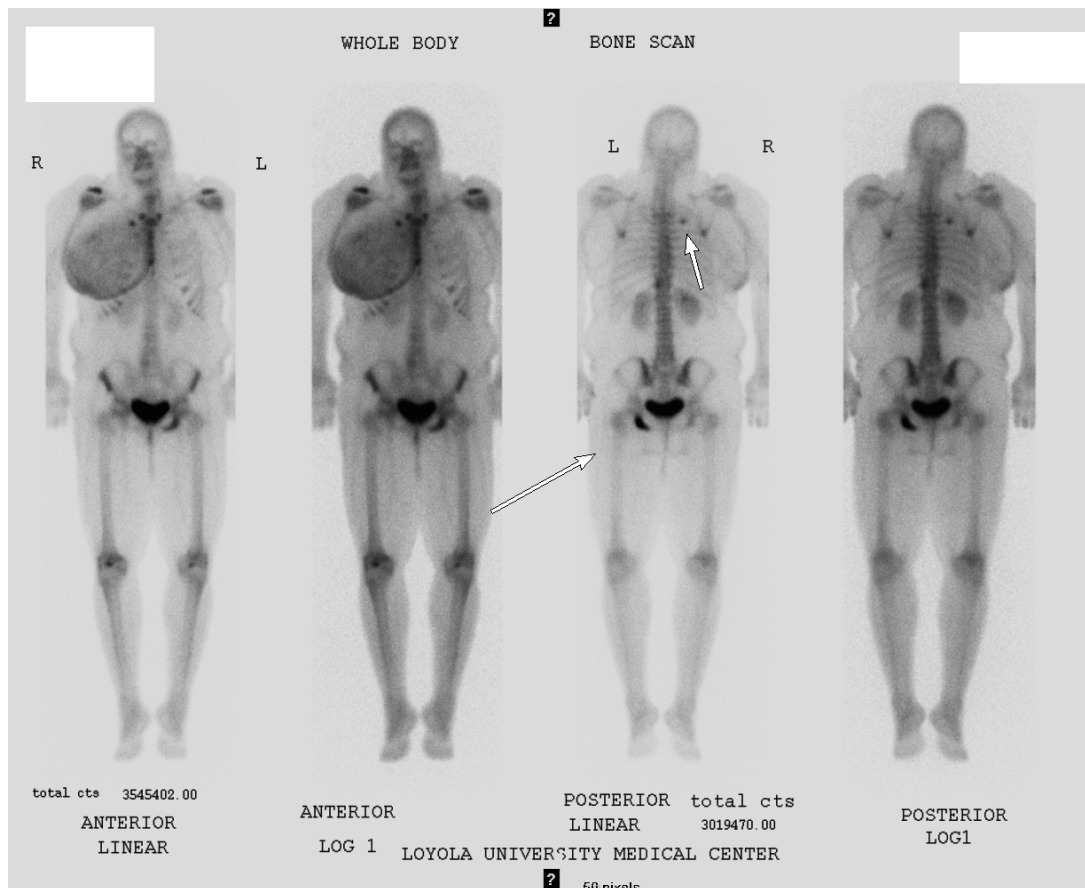


History:

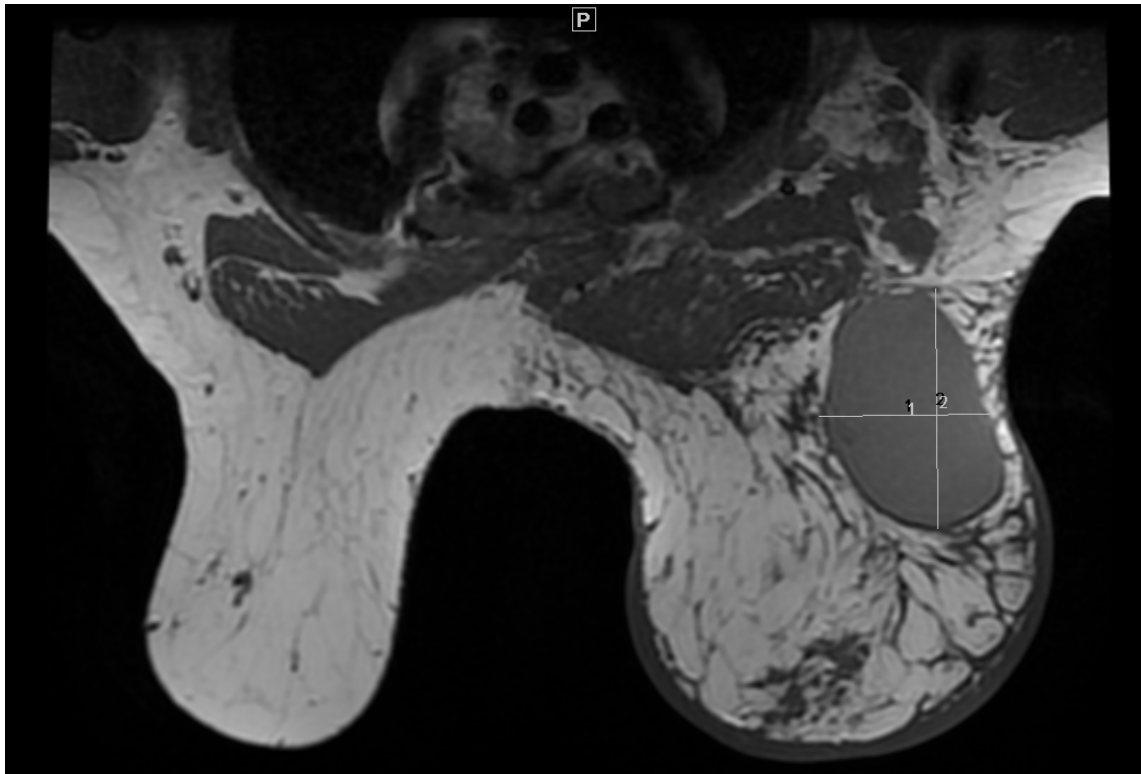
48 y/o F with newly diagnosed advanced breast cancer. Evaluate for bony metastasis.



Impression:

The right breast is significantly larger than the left, and there is also significant soft tissue uptake of radiotracer in the breast. This corresponds to the patient's breast malignancy with Peau d'Orange / lymphedema changes. There is increased uptake along the left ischium, consistent with osseous metastasis. An additional focus of increased uptake in a right upper rib anteriorly is also suspicious for osseous metastasis.

Correlative Imaging:



MRI of the breast demonstrating marked skin thickening and increased trabeculation and edema involving the right breast. There are multiple enlarged and abnormal right axillary lymph nodes and a large fluid collection within the breast.