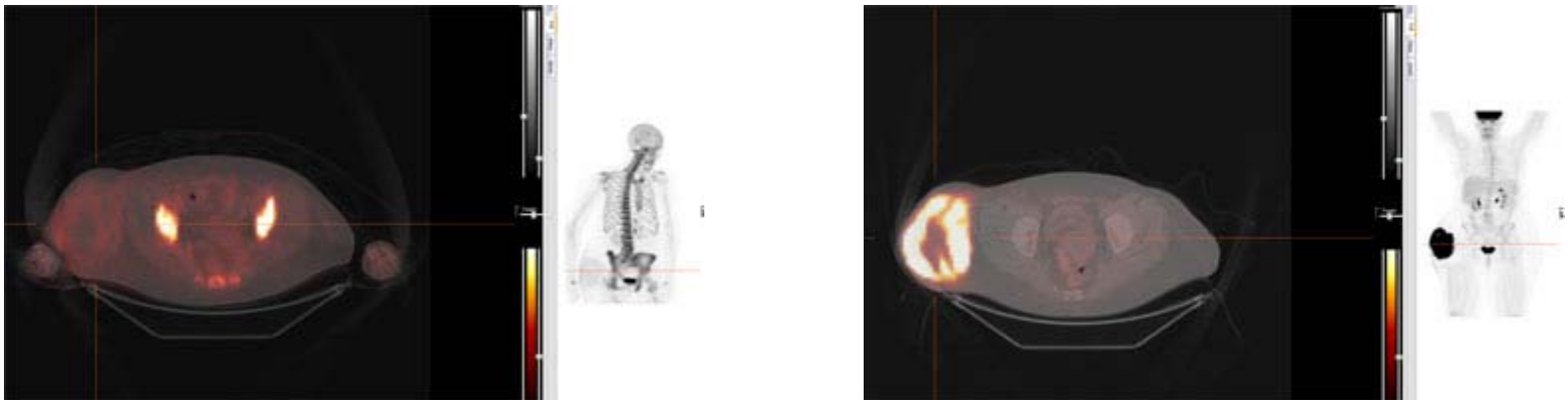


A 62 year-old female presented with a right hip mass with a past medical history of left breast cancer treated 7 years ago. She underwent F-18 NaF PET/CT bone scan (left), F-18 FDG PET/CT (right).



Findings:

F-18 NaF PET/CT shows no evidence for osseous metastatic disease. Soft tissue mass demonstrates abnormal increased uptake in the right superior and lateral thigh suspicious for malignancy, specifically sarcoma.

F-18 FDG PET/CT demonstrates a large soft tissue mass located in the soft tissues lateral to the right hip which is hypermetabolic, SUVmax of 26.1 and consistent with a malignancy.

Malignant fibrous histiocytoma, a common type of soft tissue sarcoma, was diagnosed after biopsy.