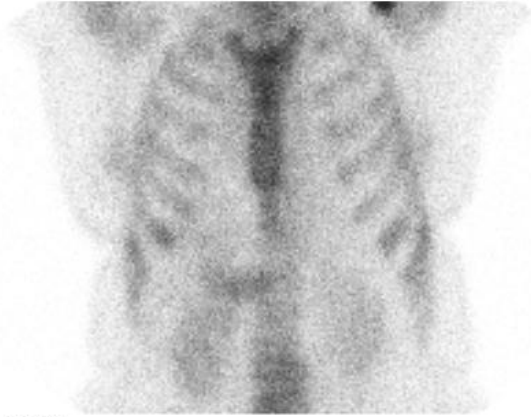
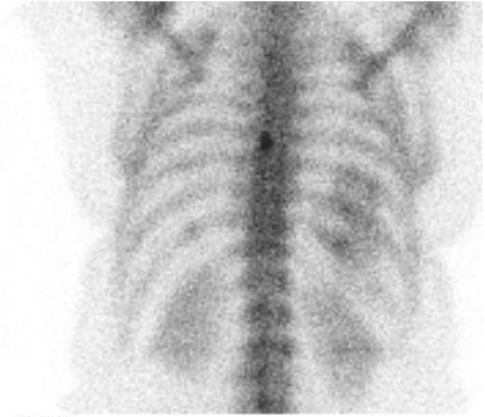

History:

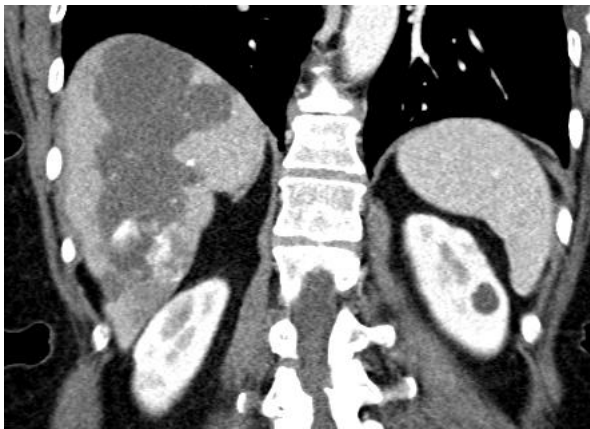
55 year old female with stage IV breast cancer who is status post chemotherapy. Tc-99m MDP spot views of the ribs are provided along with a coronal image from her CT scan.



ANT RIBS



POST RIBS



Impression:

Tc-99m MDP images show soft tissue accumulation in the liver consistent with metastatic disease.